

## Urinary Organs

### Purpose of the Exercise

To review the structure of urinary organs, to dissect a kidney, and to observe the major structures of a nephron.



### Materials Needed

Human torso model  
Kidney model  
Preserved pig (or sheep) kidney  
Dissecting tray  
Dissecting instruments  
Long knife  
Compound light microscope  
Prepared microscope slide of the following:  
Kidney section  
Ureter, cross section  
Urinary bladder  
Urethra, cross section



### Safety

- ▶ Wear disposable gloves when working on the kidney dissection.
- ▶ Dispose of the kidney and gloves as directed by your laboratory instructor.
- ▶ Wash the dissecting tray and instruments as instructed.
- ▶ Wash your laboratory table.
- ▶ Wash your hands before leaving the laboratory.

### Learning Outcomes

After completing this exercise, you should be able to

- ① Locate and identify the major structures of a kidney.
- ② Identify and sketch the major structures of a nephron.
- ③ Trace the path of filtrate through a renal nephron.
- ④ Trace the path of blood through the renal blood vessels.
- ⑤ Identify and sketch the structures of a ureter and a urinary bladder wall.
- ⑥ Trace the path of urine flow through the urinary system.



### Pre-Lab

Carefully read the introductory material and examine the entire lab. Be familiar with the structures and functions of the urinary organs from lecture or the textbook. Answer the pre-lab questions.

**Pre-Lab Questions:** Select the correct answer for each of the following questions:

1. When comparing the position of the two kidneys,
  - a. they are at the same level.
  - b. the right kidney is slightly superior to the left kidney.
  - c. the right kidney is slightly inferior to the left kidney.
  - d. the right kidney is anterior to the left kidney.
2. Cortical nephrons represent about \_\_\_\_\_ of the nephrons.
 

a. 0 %	b. 100 %
c. 20 %	d. 80 %
3. Which of the following does *not* represent one of the processes in urine formation?
  - a. secretion of renin
  - b. glomerular filtration
  - c. tubular reabsorption
  - d. tubular secretion
4. The \_\_\_\_\_ arteries and veins are located in the corticomedullary junction.
 

a. arcuate	b. renal
c. cortical radiate	d. peritubular
5. The \_\_\_\_\_ is the tube from the kidney to the urinary bladder.
 

a. urethra	b. ureter
c. renal pelvis	d. renal column
6. The trigone is a triangular, funnel-like region of the
 

a. renal cortex.	b. renal medulla.
c. urethra.	d. urinary bladder.
7. The external urethral sphincter is composed of involuntary smooth muscle.  
True \_\_\_\_\_ False \_\_\_\_\_
8. Contractions of the detrusor muscle provide the force during micturition (urination).  
True \_\_\_\_\_ False \_\_\_\_\_

**The two kidneys are** the primary organs of the urinary system. They are located in the abdominal cavity, against the posterior wall and behind the parietal peritoneum (retroperitoneal). Masses of adipose tissue associated with the kidneys hold them in place at a vertebral level between T12 and L3. The right kidney is slightly inferior due to the large mass of the liver near its superior border. Ureters force urine by means of peristaltic waves into the urinary bladder, which temporarily stores urine. The urethra conveys urine to the outside of the body.

Each kidney contains over 1 million nephrons, which serve as the basic structural and functional units of the kidney. A glomerular capsule, proximal convoluted tubule, nephron loop, and distal convoluted tubule compose the microscopic, multicellular structure of a relatively long nephron tubule, which drains into a collecting duct. Approximately 80% of the nephrons are cortical nephrons with short nephron loops, while the remaining represent juxtamedullary nephrons, with long nephron loops extending deeper into the renal medulla. An elaborate network of blood vessels surrounds the entire nephron. Glomerular filtration, tubular reabsorption, and tubular secretion represent three processes resulting in urine as the final product.

A variety of functions occur in the kidneys. They remove metabolic wastes from the blood; help regulate blood volume, blood pressure, and pH of blood; control water and electrolyte concentrations; and secrete renin and erythropoietin. Renin functions in regulation of blood pressure and erythropoietin helps regulate red blood cell production.

## Procedure A—Kidney Structure

- Study figures 1 and 2 and the list of structures and descriptions.
- Observe the human torso model and the kidney model. Locate the following:

**kidneys**—paired retroperitoneal organs

**ureters**—paired tubular organs about 25 cm long that transport urine from kidney to urinary bladder

**urinary bladder**—single muscular storage organ for urine

**urethra**—conveys urine from urinary bladder to external urethral orifice

**renal sinus**—hollow chamber of kidney

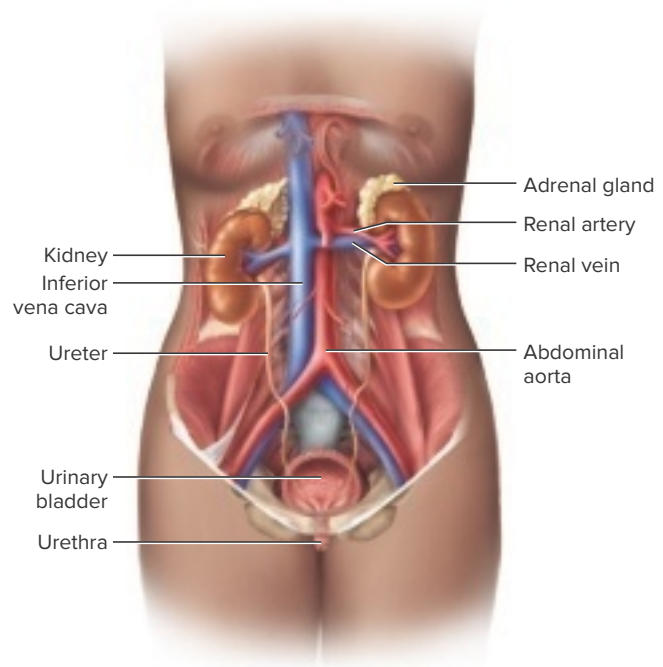
**renal pelvis**—funnel-shaped sac at superior end of ureter; receives urine from major calyces

- major calyces—2–3 major converging branches into renal pelvis; receive urine from minor calyces
- minor calyces—small subdivisions of major calyces; receive urine from papillary ducts within renal papillae

**renal medulla**—deep region of kidney

- renal pyramids—6–10 conical regions composing most of renal medulla

**FIGURE 1** The urinary system and associated structures.



- renal papillae—projections at ends of renal pyramids with openings into minor calyces

**renal cortex**—superficial region of kidney

**renal columns**—extensions of renal cortical tissue between renal pyramids

**nephrons**—functional units of kidneys

- cortical nephrons—80% of nephrons close to surface
- juxtamedullary nephrons—20% of nephrons close to medulla

- To observe the structure of a kidney, follow these steps:
  - Obtain a preserved pig or sheep kidney and rinse it with water to remove as much of the preserving fluid as possible.
  - Carefully remove any adipose tissue from the surface of the specimen.
  - Locate the following features:
 

**fibrous (renal) capsule**—protective membrane that encloses kidney

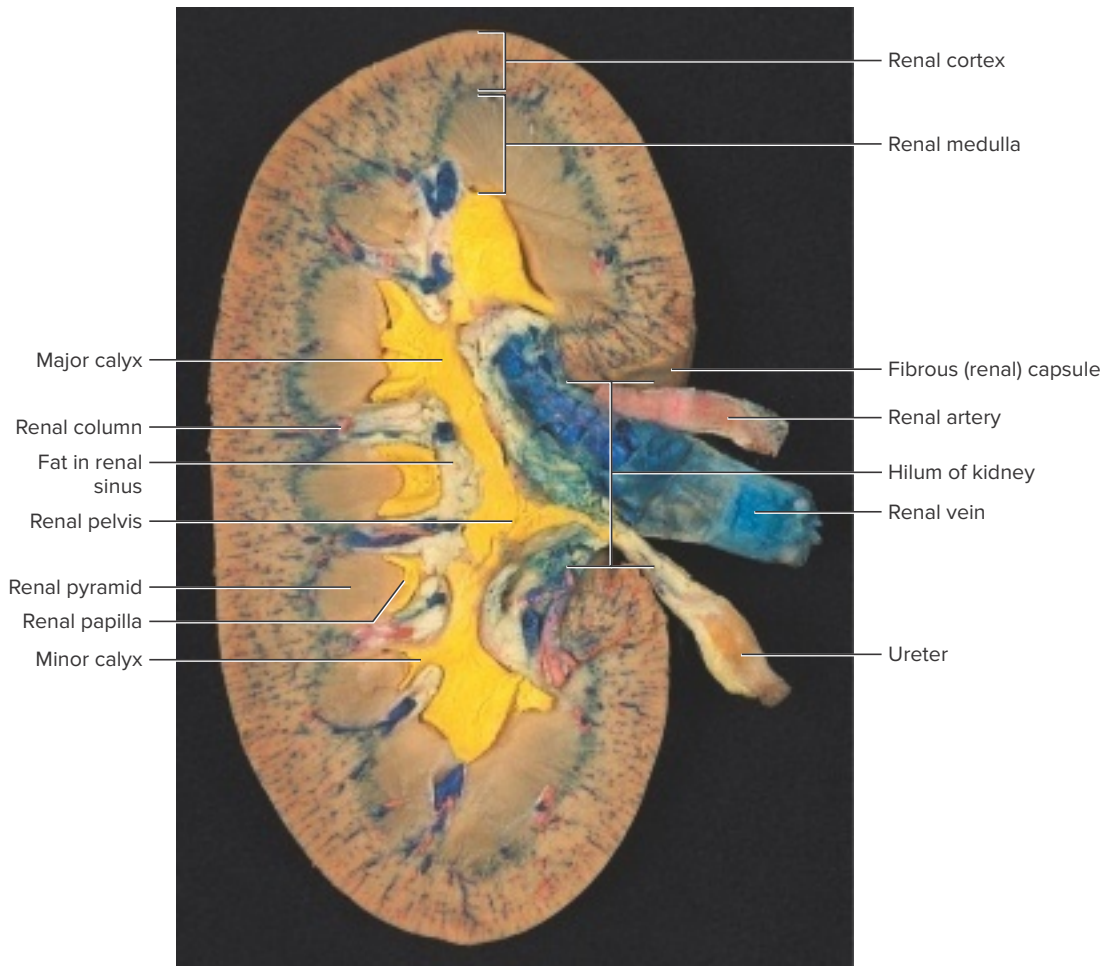
**hilum of kidney**—indented region containing renal artery and vein and ureter

**renal artery**—large artery arising from abdominal aorta

**renal vein**—large vein that drains into inferior vena cava

**ureter**—transports urine from renal pelvis to urinary bladder
  - Use a long knife to cut the kidney in half longitudinally along the frontal plane, beginning on the convex border.

**FIGURE 2** Frontal section of a pig kidney that has a triple injection of latex (*red* in the renal artery, *blue* in the renal vein, and *yellow* in the ureter and renal pelvis).



- e. Rinse the interior of the kidney with water, and using figure 2 as a reference, locate the following:

**renal pelvis**

- major calyces
- minor calyces

**renal cortex**

**renal columns**

**renal medulla**

- renal pyramids
- renal papillae

4. Complete Part A of Laboratory Assessment 28.

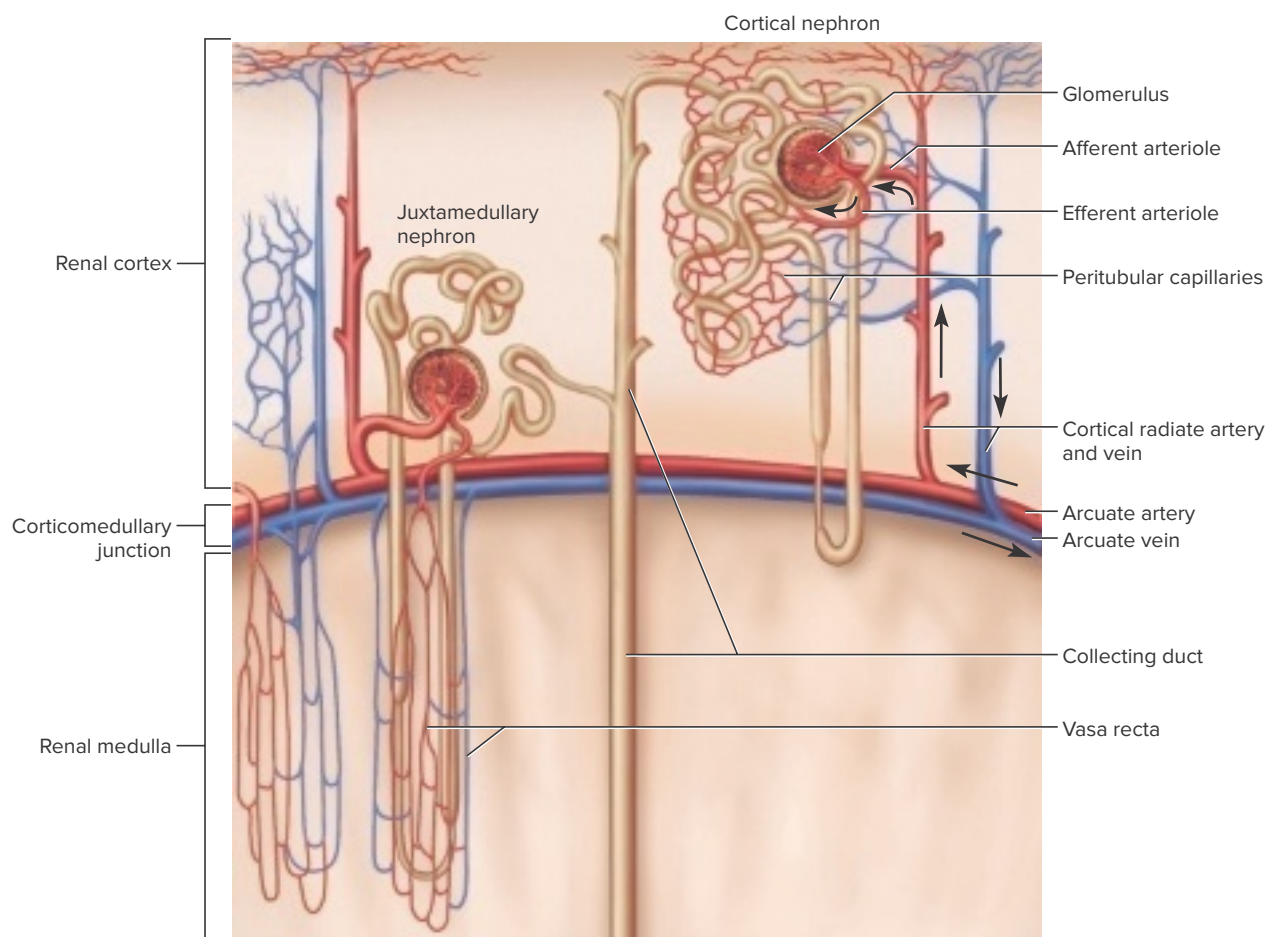
## Procedure B—Renal Blood Vessels and Nephrons

1. Study figures 3 and 4 illustrating renal blood vessels and structures of a nephron. The arrows within the figures indicate blood flow and tubular fluid flow.
2. Obtain a microscope slide of a kidney section and examine it using low-power magnification. Locate the *renal capsule*, the *renal cortex* (which appears somewhat

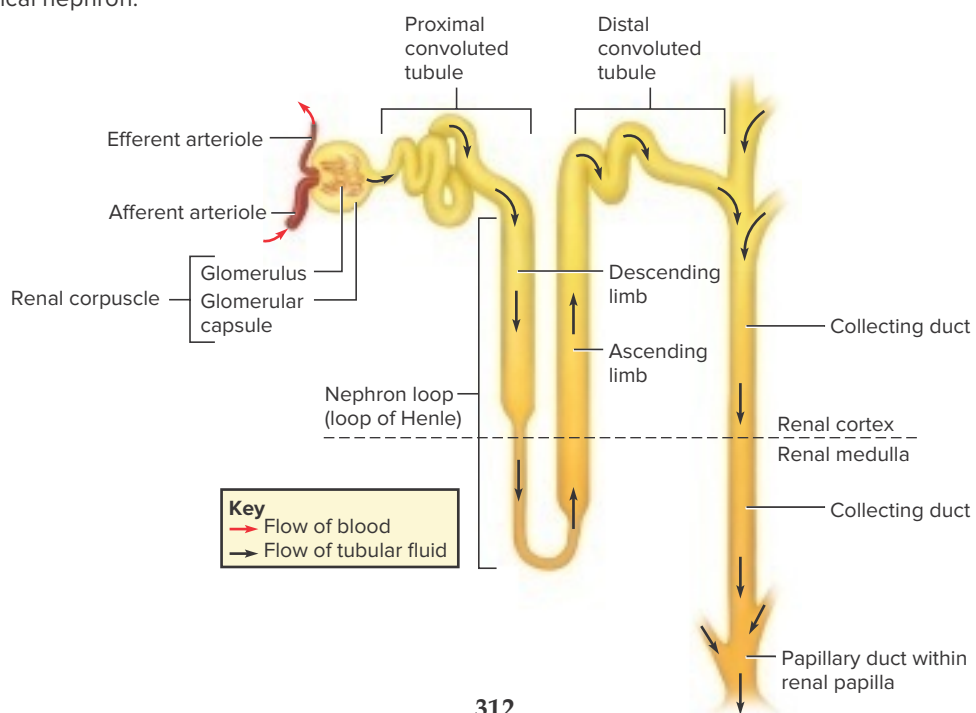
granular and may be more darkly stained than the other renal tissues), and the *renal medulla* (fig. 5).

3. Examine the renal cortex using high-power magnification. Locate a *renal corpuscle*. These structures appear as isolated circular areas. Identify the *glomerulus*, the capillary cluster inside the corpuscle, and the *glomerular (Bowman's) capsule*, which appears as a clear area surrounding the glomerulus. A glomerulus and a glomerular capsule compose a *renal corpuscle*. Also note the numerous sections of renal tubules that occupy the spaces between renal corpuscles (fig. 5a).
4. Prepare a labeled sketch of a representative section of the renal cortex in Part B of the laboratory assessment.
5. Examine the renal medulla using high-power magnification. Identify longitudinal and cross-sectional views of various collecting ducts. These ducts are lined with simple epithelial cells, which vary in shape from squamous to cuboidal (fig. 5b).
6. Prepare a labeled sketch of a representative section of the renal medulla in Part B of the laboratory assessment.
7. Complete Part C of the laboratory assessment.

**FIGURE 3** Renal blood vessels associated with cortical and juxtamedullary nephrons. The arrows indicate the flow of blood. Blood from the renal artery flows through a segmental artery and an interlobar artery to the arcuate artery. Blood from an arcuate vein flows through an interlobar vein to the renal vein.

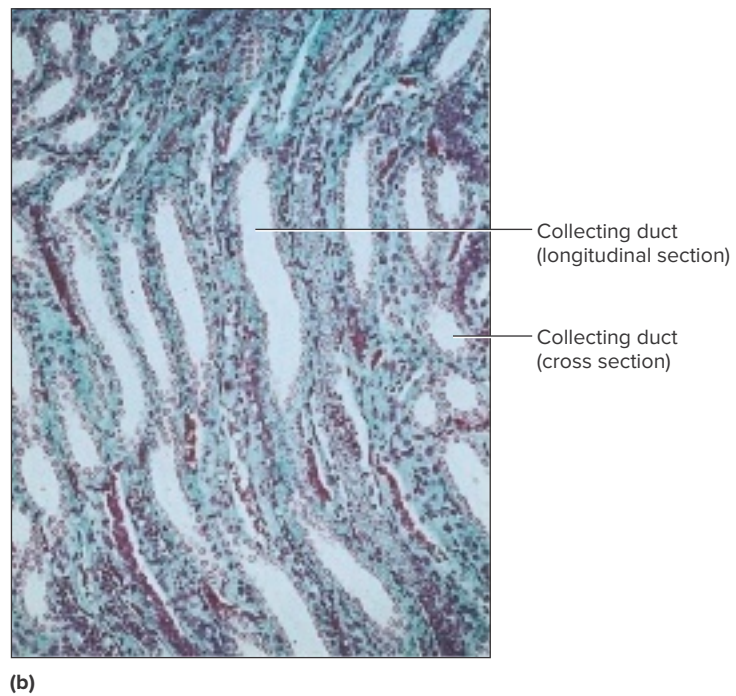
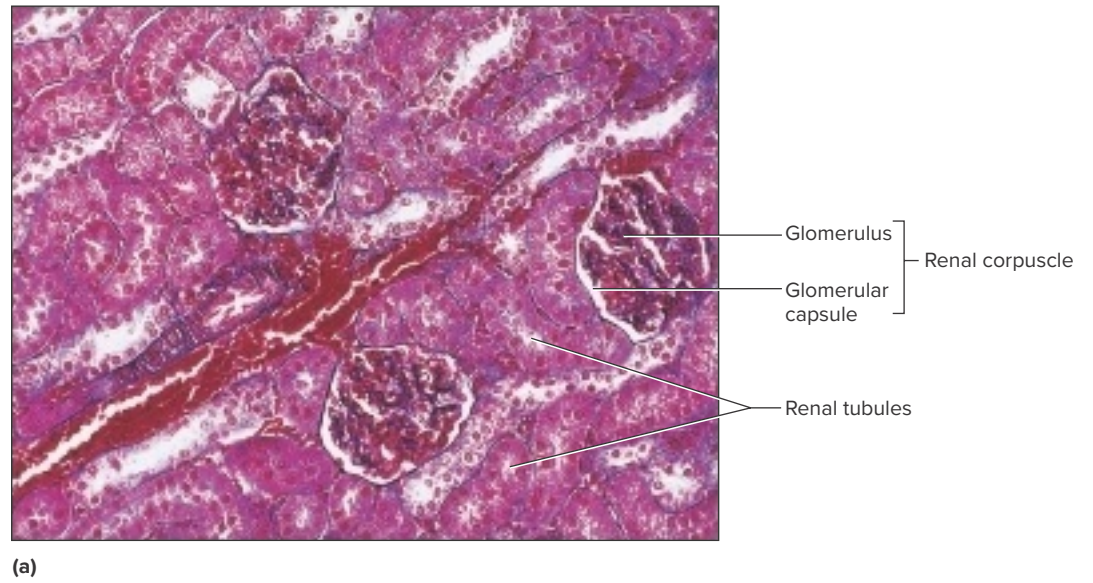


**FIGURE 4** Structure of a nephron with arrows indicating the flow of tubular fluid. The corticomedullary junction is typical for a cortical nephron.





**FIGURE 5** (a) Micrograph of a section of the renal cortex (220 $\times$ ). (b) Micrograph of a section of the renal medulla (80 $\times$ ).



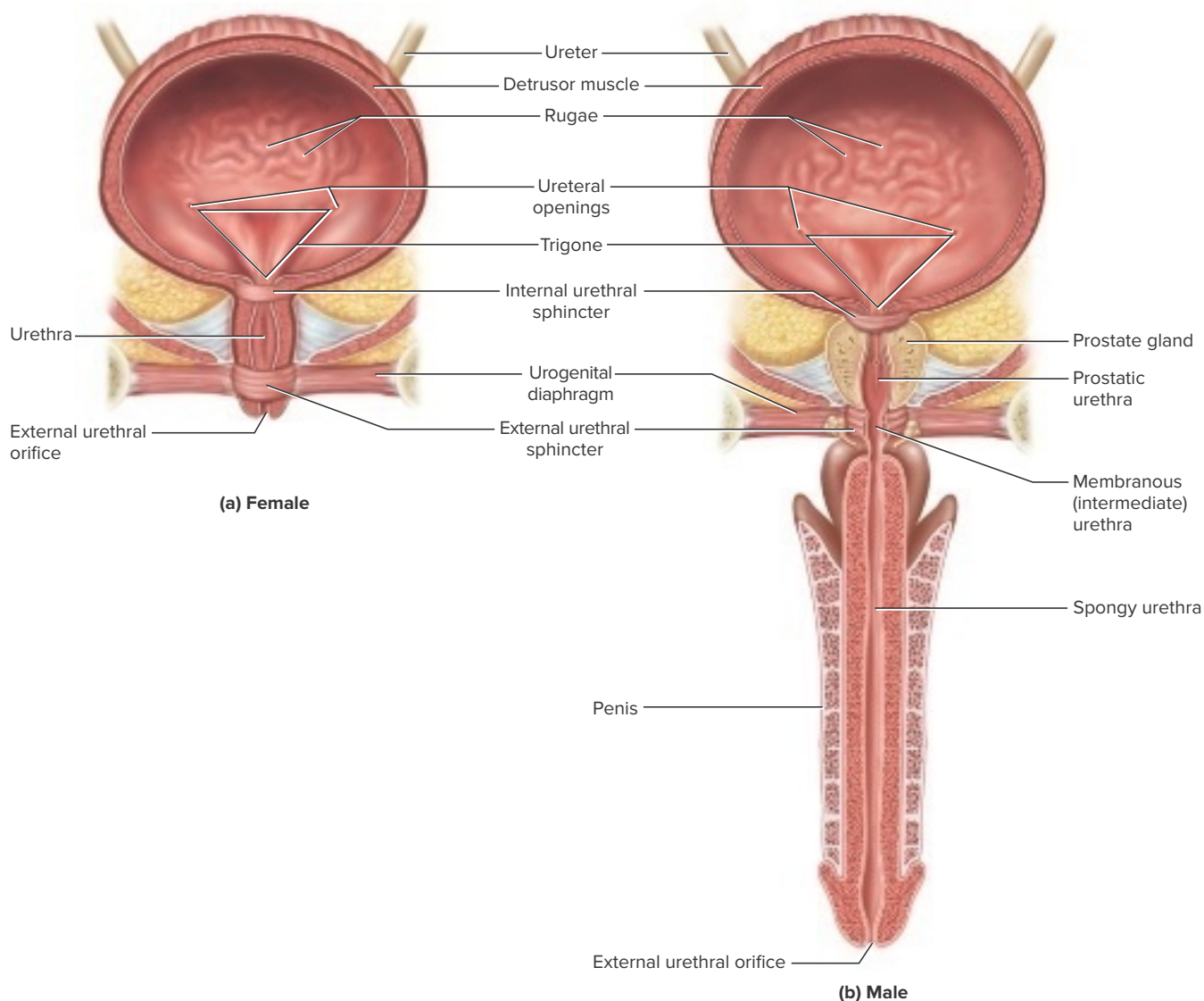
## Procedure C—Ureter, Urinary Bladder, and Urethra

The *ureters* are paired tubes about 25 cm (10 inches) long extending from the renal pelvis to the *ureteral openings* (*ureteric orifices*) of the *urinary bladder*. Peristaltic waves, created from rhythmic contractions of smooth muscle, occur about every 30 seconds, transporting the urine toward the urinary bladder. The bladder possesses mucosal folds called *rugae* that enable it to distend for temporary urine storage. Coarse bundle layers of smooth muscle compose the somewhat broad *detrusor muscle*. The triangular floor of the bladder, the *trigone*, is bordered by the two ureteral openings and the opening into the urethra, which is surrounded by the *internal urethral sphincter*. The internal urethral sphincter is formed by a thickened region of the detrusor muscle (fig. 6).

Although the bladder can hold about 600 mL of urine, the desire to urinate from the pressure of a stretched bladder occurs when the bladder has about 150–200 mL of urine. During *micturition* (*urination*) the powerful detrusor muscle contracts, and the internal urethral sphincter is forced open. The *external urethral sphincter*, at the level of the urogenital diaphragm, is under somatic control. Because the external urethral sphincter is skeletal muscle, there is considerable voluntary control over the voiding of urine.

The *urethra* extends from the exit of the urinary bladder to the *external urethral orifice*. In the female the urethra is about 4 cm (1.5 inches) long. In the male, the urethra includes passageways for both urine and semen and extends the length of the penis. The male urethra can be divided into three sections: prostatic urethra, membranous (intermediate) urethra, and spongy urethra (fig. 6b). A total length of about

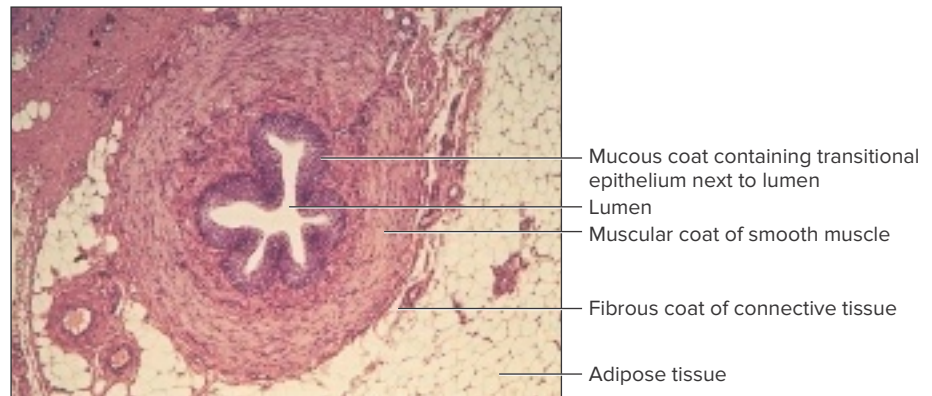
**FIGURE 6** Ureters and frontal sections of urinary bladder and urethra of (a) female and (b) male.



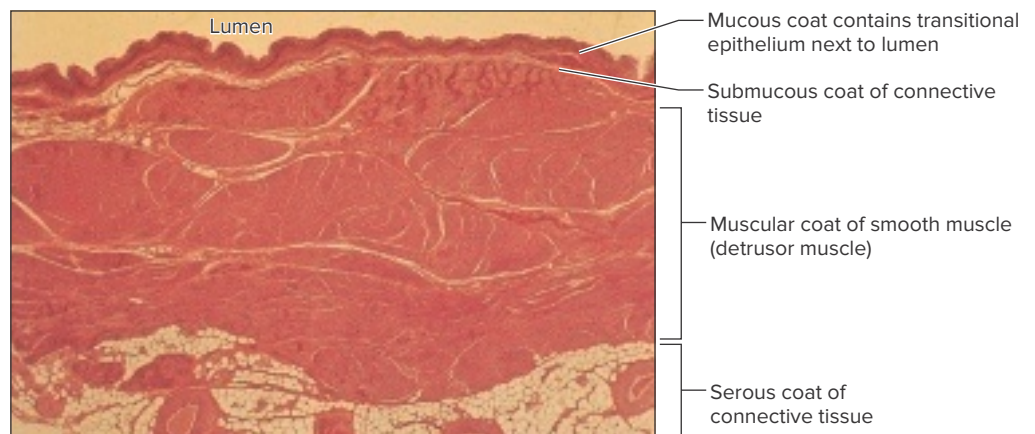
20 cm (8 inches) would be characteristic for the urethra of a male.

1. Obtain a microscope slide of a cross section of a ureter and examine it using low-power magnification. Locate the *mucous coat* layer next to the lumen. Examine the middle *muscular coat* composed of longitudinal and circular smooth muscle cells responsible for the peristaltic waves that propel urine from the kidneys to the urinary bladder. The outer *fibrous coat*, composed of connective tissue, secures the ureter in the retroperitoneal position (fig. 7).
2. Examine the mucous coat using high-power magnification. The specialized tissue is transitional epithelium, which allows changes in its thickness when unstretched and stretched.
3. Prepare a labeled sketch of a ureter in Part D of the laboratory assessment.
4. Obtain a microscope slide of a segment of the wall of a urinary bladder and examine it using low-power magnification. Examine the *mucous coat* next to the lumen and the *submucous coat* composed of connective tissue just beneath the mucous coat. Examine the *muscular coat* composed of bundles of smooth muscle fibers interlaced in many directions. This thick muscular layer is called the *detrusor muscle* and functions in the elimination of urine. Also note the outer *serous coat* of connective tissue (fig. 8).
5. Examine the mucous coat using high-power magnification. The tissue is transitional epithelium, which allows changes in its thickness from unstretched when the bladder is empty to stretched when the bladder distends with urine.

**FIGURE 7** Micrograph of a cross section of a ureter (75×).

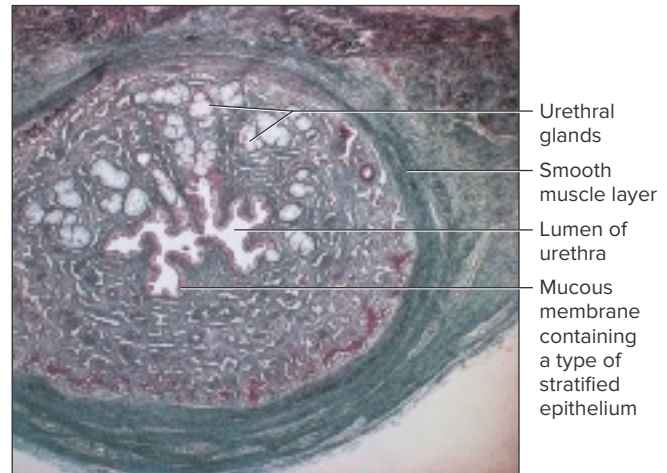


**FIGURE 8** Micrograph of a segment of the human urinary bladder wall (6×).



6. Prepare a labeled sketch of a segment of the urinary bladder wall in Part D of the laboratory assessment.
7. Obtain a microscope slide of a cross section of a urethra and examine it using low-power magnification. Locate the muscular coat composed of smooth muscle fibers. Locate groups of mucous glands, called *urethral glands*, in the urethral wall that secrete protective mucus into the lumen of the urethra. Examine the mucous coat using high-power magnification. The mucous membrane is composed of a type of stratified epithelium. The specific type of stratified epithelium varies from transitional, to stratified columnar, to stratified squamous epithelium between the urinary bladder and the external urethral orifice. Depending upon where the section of the urethra was taken for the preparation of the microscope slide, the type of stratified epithelial tissue represented could vary (fig. 9).
8. Complete Part E of the laboratory assessment.

**FIGURE 9** Cross section through the urethra (10 $\times$ ).





Name \_\_\_\_\_

Date \_\_\_\_\_

Section \_\_\_\_\_

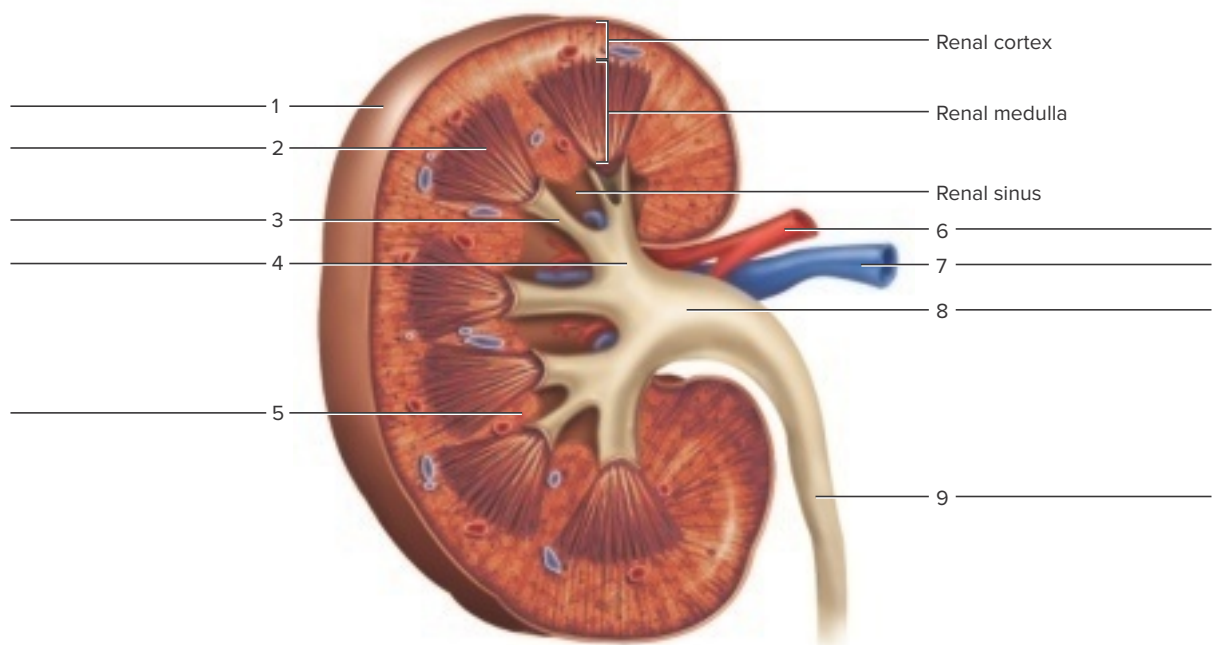
The **A** corresponds to the indicated outcome(s) found at the beginning of the laboratory exercise.

## Urinary Organs

### Part A Assessments

1. Label the features indicated in figure 10 of a kidney (frontal section).

**FIGURE 10** Label the structures in the frontal section of a kidney. **A**



2. Match the terms in column A with the descriptions in column B. Place the letter of your choice in the space provided. **A**


#### Column A

- a. Calyces
- b. Hilum of kidney
- c. Nephron
- d. Renal column
- e. Renal cortex
- f. Renal papilla
- g. Renal pelvis
- h. Renal pyramid
- i. Renal sinus

#### Column B

- \_\_\_\_\_ 1. Superficial region around the renal medulla
- \_\_\_\_\_ 2. Branches of renal pelvis to renal papillae
- \_\_\_\_\_ 3. Conical mass of tissue within renal medulla
- \_\_\_\_\_ 4. Projection with tiny openings into a minor calyx
- \_\_\_\_\_ 5. Hollow chamber within kidney
- \_\_\_\_\_ 6. Microscopic functional unit of kidney
- \_\_\_\_\_ 7. Located between renal pyramids
- \_\_\_\_\_ 8. Superior funnel-shaped end of ureter inside the renal sinus
- \_\_\_\_\_ 9. Medial depression for blood vessels and ureter to enter kidney chamber



## Part B Assessments

Sketch a representative section of the renal cortex and the renal medulla. Label the glomerulus, glomerular capsule, and sections of renal tubules in the renal cortex. Label a longitudinal section and cross section of a collecting duct in the renal medulla. 

Renal cortex (____×)	Renal medulla (____×)
----------------------	-----------------------

## Part C Assessments

Complete the following:

1. Distinguish between a renal corpuscle and a renal tubule.   
\_\_\_\_\_  
\_\_\_\_\_  
\_\_\_\_\_
2. Number the following structures to indicate their respective positions in relation to the nephron. Assign the number 1 to the structure nearest the glomerulus.   
  
\_\_\_\_ Ascending limb of nephron loop  
\_\_\_\_ Collecting duct  
\_\_\_\_ Descending limb of nephron loop  
\_\_\_\_ Distal convoluted tubule  
\_\_\_\_ Glomerular capsule  
\_\_\_\_ Proximal convoluted tubule  
\_\_\_\_ Papillary duct in renal papilla

3. Number the following structures (the list does not include all possible blood vessels) to indicate their respective positions in the blood pathway within the kidney. Assign the number 1 to the vessel nearest the abdominal aorta. **4**


- \_\_\_\_\_ Afferent arteriole
- \_\_\_\_\_ Arcuate artery
- \_\_\_\_\_ Arcuate vein
- \_\_\_\_\_ Cortical radiate artery
- \_\_\_\_\_ Cortical radiate vein
- \_\_\_\_\_ Efferent arteriole
- \_\_\_\_\_ Glomerulus
- \_\_\_\_\_ Peritubular capillary (or vasa recta)
- \_\_\_\_\_ Renal artery
- \_\_\_\_\_ Renal vein

## Part D Assessments

Sketch a cross section of a ureter and label the three layers and the lumen. Sketch a segment of a urinary bladder and label the four layers and the lumen. **5**

Ureter ( _____ ×)	Urinary bladder ( _____ ×)
-------------------	----------------------------

## Part E Assessments

Number the following structures to indicate respective positions in the pathway of urine flow in a male. Assign the number 1 to the structure nearest the papillary duct in a renal papilla. 

- \_\_\_\_\_ External urethral orifice
- \_\_\_\_\_ Major calyx
- \_\_\_\_\_ Membranous urethra
- \_\_\_\_\_ Minor calyx
- \_\_\_\_\_ Prostatic urethra
- \_\_\_\_\_ Renal pelvis
- \_\_\_\_\_ Spongy urethra
- \_\_\_\_\_ Ureter
- \_\_\_\_\_ Ureteral opening
- \_\_\_\_\_ Urinary bladder